Journal Endo Sapiens

Case Report

Guided Endodontic Access in a Clinically Intact Mandibular Premolar with Pulp Canal Obliteration: A Case Report

Abdelhak Kiouah[1,*]

Abstract

A 40-year-old medically healthy woman presented with tenderness to percussion of tooth 28 (mandibular right first premolar) and an associated periapical radiolucency. The crown was clinically intact. There was no caries, restoration, discoloration, visible crack, or history of acute dental trauma. Cold testing was negative, and cone-beam computed tomography (CBCT) demonstrated pulp canal obliteration extending through the middle third of the root. A patent canal lumen was identified apical to the calcified segment. Because conventional access was considered unpredictable and carried a substantial risk of excessive dentin removal, canal deviation, or perforation, a static guided endodontic approach was selected. A tooth-supported guide was designed by merging the CBCT dataset with an intraoral optical scan and was fabricated by stereolithographic three-dimensional printing. A 1.0-mm-diameter, 28-mm-long WSR drill (atec Dental GmbH, Ebringen, Germany) was directed through a metallic sleeve to the planned canal location. The canal was negotiated, instrumented, irrigated with sonic activation, and obturated with gutta-percha and a premixed hydraulic calcium-silicate sealer. The access cavity was restored with an adhesive resin composite. Symptoms resolved within 1 week. At 6 and 12 months, the tooth remained asymptomatic and functional, with progressive radiographic reduction of the periapical radiolucency. The patient's history of nocturnal clenching suggested an occult crack-related pathway for bacterial ingress, although this etiology could not be confirmed. This case illustrates the diagnostic uncertainty of pulp necrosis in an apparently intact tooth and the value of carefully planned guided access for conservative canal localization in a calcified mandibular premolar.

Keywords: calcified canal; cone-beam computed tomography; guided endodontics; pulp canal obliteration; pulp necrosis; static navigation

[1]Private endodontic practice in Brussels, Belgium

Corresponding author:
Abdelhak Kiouah. Email: Kioura@hotmail.com;
Phone: +32 (470) 126-267

Received for publication Jun 29, 2026; accepted for publication Jul 10, 2026.
Copyright © 2026 Dentoki OÜ
https://doi.org/10.71347/sf9ym47a

Introduction

Pulp necrosis and apical periodontitis usually develop when caries, restorative leakage, or traumatic injury creates a pathway for microbial entry into the pulp space. When the affected tooth has a clinically intact crown and no known history of trauma, the diagnosis and etiologic interpretation become more difficult. An incomplete coronal crack may extend through dentin without producing an obvious surface defect, an isolated periodontal defect, or a radiographically visible fracture line. Such occult cracks may nevertheless permit bacterial penetration and ultimately result in pulpal necrosis and apical inflammation (Lynch & McConnell, 2002; Berman & Kuttler, 2010; Ricucci & Siqueira, 2010). Repetitive parafunctional loading has been associated with crack initiation and propagation, but a clinical history of clenching or bruxism alone cannot establish causation (Banerji et al., 2010a, 2010b).

Pulp canal obliteration introduces a separate technical challenge. Calcification may obscure the canal orifice and eliminate the visual landmarks used during conventional access preparation. Continued freehand drilling in search of the canal can remove substantial coronal and pericervical dentin, alter the original canal trajectory, or result in perforation. These risks are particularly relevant in mandibular premolars, which may have narrow mesiodistal root dimensions and limited tolerance for directional error (Clark & Khademi, 2010; Krastl et al., 2016; Moreno-Rabié et al., 2020).

Static guided endodontics adapts principles developed for computer-assisted implant surgery (Connert et al., 2022, 2025). A CBCT dataset is merged with a surface scan of the dental arch, the desired drill path is planned virtually, and a tooth-supported template directs a small-diameter drill toward the remaining patent canal. Laboratory investigations have shown that guided access can improve canal localization and reduce substance loss compared with conventional freehand preparation. Nevertheless, the accuracy of guided access depends on image quality, dataset registration, guide fit, sleeve tolerance, and the rigidity of the drilling system (Zehnder et al., 2016; Connert et al., 2017, 2019). Cone beam computed tomography should be used only when the expected diagnostic or treatment benefit justifies the radiation exposure and when a limited field of view can answer the clinical question (Patel et al., 2019).

This case report describesthe diagnosis and treatment of pulp necrosis with symptomatic apical periodontitis in a clinically intact mandibular right first premolar with extensive pulp canal obliteration. A fully guided digital workflow was used to localize the canal conservatively. Particular attention was given to the uncertainty of the suspected crack-related etiology, the rationale for guided access, and the limitations that should temper interpretation of a favorable single-case outcome.

Case presentation

A 40-year-old woman with no relevant medical conditions was referred for evaluation of pain associated with tooth 28. The patient reported discomfort during mastication and tenderness when the tooth was tapped. She denied a history of acute dental trauma but reported several years of nocturnal clenching.

Clinical examination showed no caries, restoration, coronal discoloration, swelling, or sinus tract. No crack was visible under magnification. Periodontal probing depths were physiologic and did not exceed 3 mm. There was no isolated deep probing defect or clinical attachment loss. Tooth mobility was within normal limits. The tooth was tender to vertical percussion and did not respond to cold testing with Endo-Ice (Coltène/Whaledent, Inc., Altstätten, Switzerland). The adjacent and contralateral control teeth responded normally.

Periapical imaging demonstrated an apical

radiolucency and marked narrowing of the canal space. Limited-field CBCT revealed a single root and a single canal. Pulp canal obliteration extended through the middle third of the root. A discernible canal lumen was visible apical to the calcified segment (Figures 1-2). No additional root, canal, or resorptive abnormality was observed. The combined findings supported the diagnosis of pulp necrosis and symptomatic apical periodontitis.

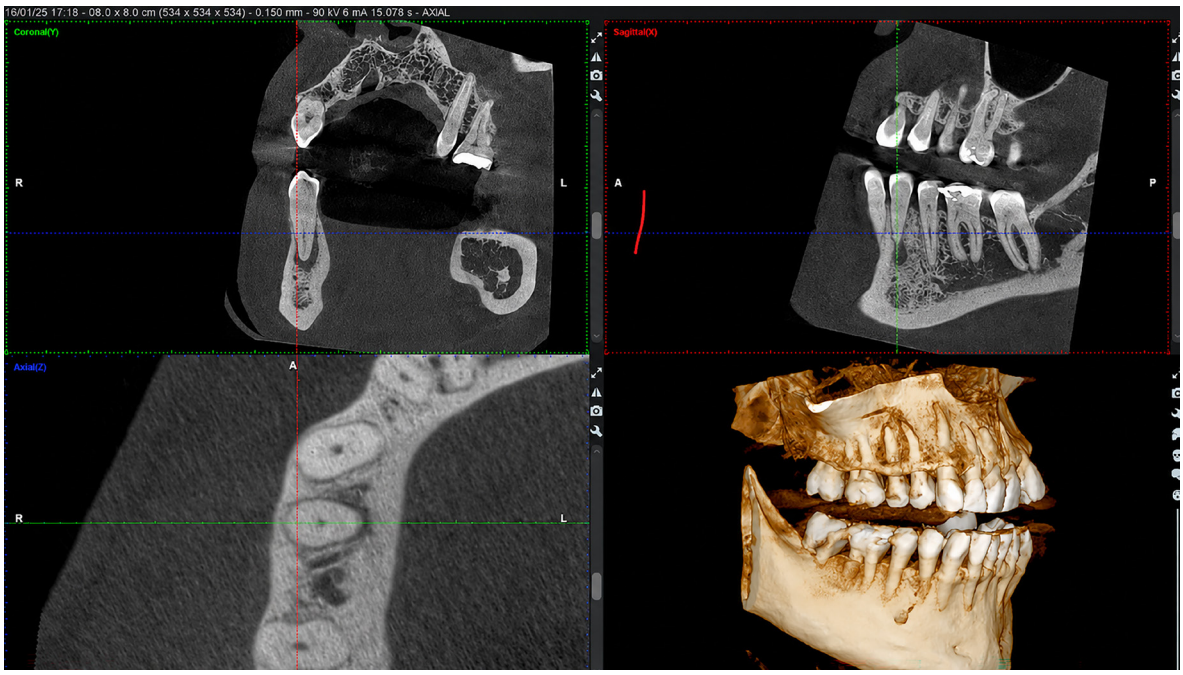

Fig. 1. Preoperative CBCT images of tooth 28 with a periapical radiolucency and extensive pulp canal obliteration extending through the middle third of the root.

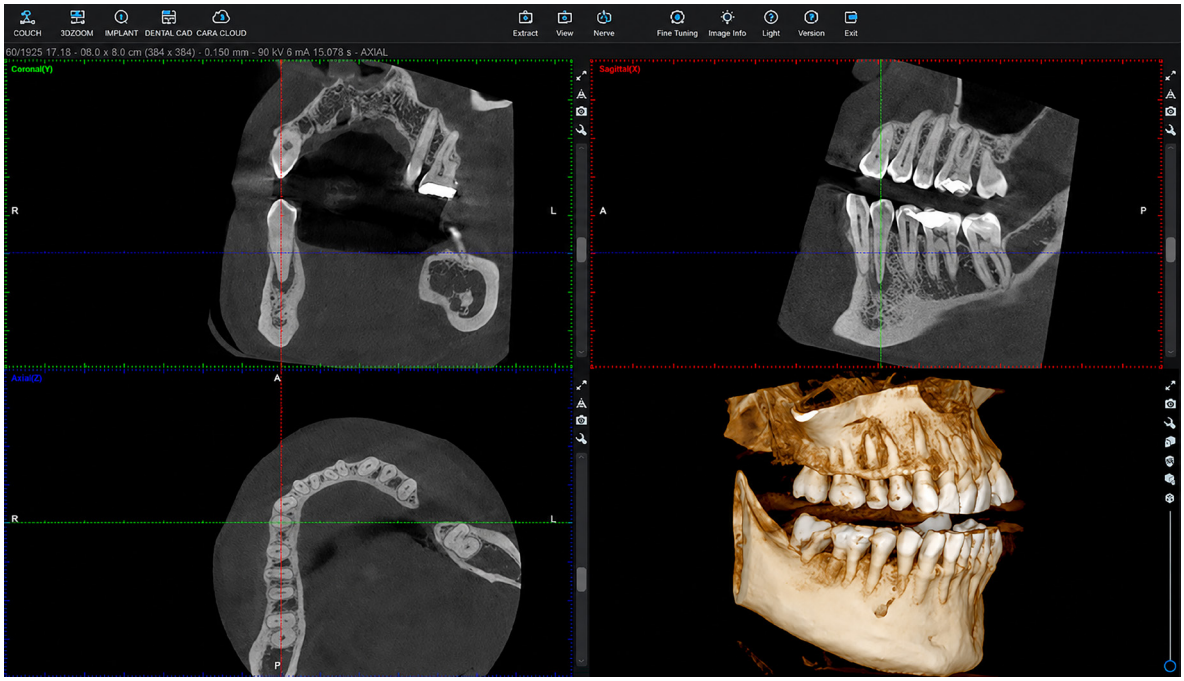

Fig. 2. CBCT analysis showing the residual canal lumen apical to the calcified segment. Identification of this patent segment permitted virtual planning of the guided access trajectory.

Diagnosis and treatment planning

The definitive diagnosis was pulp necrosis with symptomatic apical periodontitis in tooth 28. The absence of caries, restorations, visible coronal defects, and known trauma made the route of pulpal infection uncertain. An occult dentinal crack related to repetitive parafunctional loading was considered a plausible explanation. However, it was regarded as a suspected but unconfirmed etiology because no crack could be directly visualized or otherwise confirmed.

Conventional freehand access was considered to have a high risk of unnecessary dentin removal and directional error because the canal was not identifiable through the coronal and middle thirds. The presence of a detectable apical canal lumen and the relatively straight root anatomy made static guided access feasible. After discussion of the benefits, limitations, alternatives, and procedural risks, the patient consented to guided nonsurgical root canal treatment.

Guided endodontic workflow

A high-resolution CBCT scan was acquired with a Planmeca ProMax 3D unit (Planmeca, Helsinki, Finland) using a voxel size of 150 µm, 90 kV, 5 mA, and a medium field of view. An optical scan of the mandibular arch was obtained with a third-generation TRIOS scanner (3Shape, Copenhagen, Denmark) (Figure 3).

The CBCT Digital Imaging and Communications in Medicine (DICOM) dataset and the standard tessellation language (STL) file from the optical scan were imported into DTX Studio Implant software (Nobel Biocare, Zurich, Switzerland). Dataset matching and virtual planning were completed by the Advimago Imaging Center (Brussels, Belgium). After verification of surface superimposition, a drill trajectory was planned from the occlusal surface to the residual canal lumen, with the path centered within the root and positioned to minimize dentin removal (Figure 4). The use of merged three-dimensional datasets and a constrained drill path



Fig. 3. Digital intraoral scan of the mandibular arch used for surface registration and guide design.

is consistent with established guided endodontic workflows (Zehnder et al., 2016; Connert et al., 2017).

A tooth-supported guide was designed and fabricated with a stereolithography three-dimensional printer (Formlabs Inc., Somerville, MA, USA). The guide incorporated a titanium sleeve with a 1.0-mm internal diameter, 3.5-mm external diameter, and 5-mm length. The guide was inspected extraorally and then seated intraorally to confirm complete, stable adaptation without rocking (Figure 5).

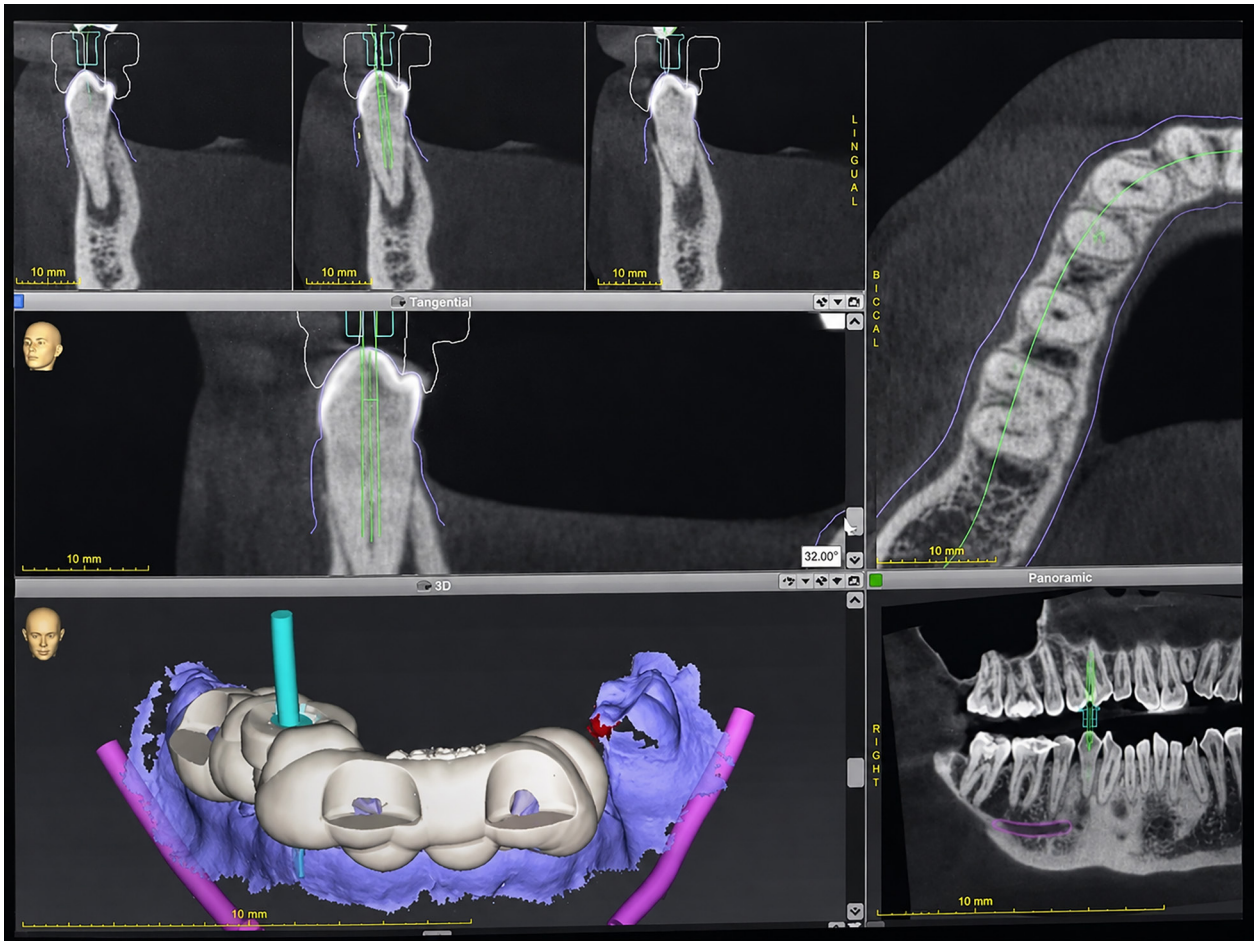

Fig. 4. Virtual planning after CBCT-surface scan registration. The planned drill path is directed toward the patent apical portion of the canal while remaining centered within the root.

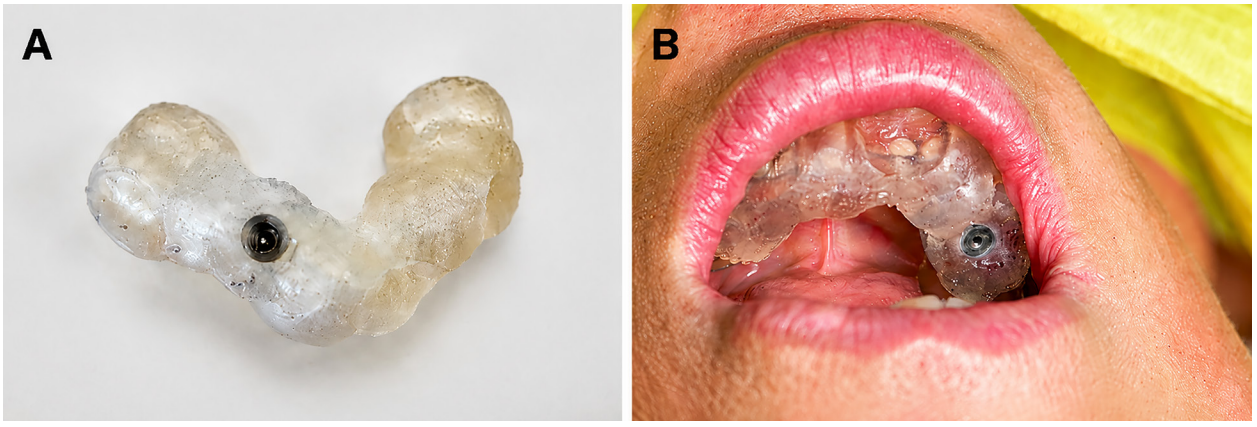

Fig. 5. Tooth-supported guide. (A) Extraoral view of the three-dimensionally printed template and metallic sleeve. (B) Intraoral verification of guide seating before access preparation.

Treatment procedure

After local anesthesia and rubber dam isolation, the guide was reseated and its stability was reconfirmed. Guided access was performed using a 28-mm-long, 1.0-mm-diameter WSR drill (atec Dental GmbH, Ebringen, Germany) through a StecoGuide titanium sleeve (steco-system-technik GmbH & Co. KG, Hamburg, Germany). The drill was used in controlled increments and withdrawn repeatedly to permit debris removal and visual verification. An intraoperative periapical radiograph confirmed alignment of the drill with the planned canal path (Figure 6). The calcified segment was traversed without clinically evident deviation or perforation.

After the residual canal lumen was reached, negotiation was completed with stainless steel C-Pilot files in sizes 06, 08, and 10 (VDW GmbH, Munich, Germany). Working length was established electronically with a Propex II apex locator (Dentsply Sirona, Ballaigues, Switzerland) at 20.5 mm and was confirmed radiographically. A master cone radiograph was obtained before obturation (Figure 7).

Mechanical preparation was performed in a crown-down sequence with SlimShaper nickel-titanium rotary instruments (Zarc4Endo, Gijón, Spain). Shaping was completed with ZS1, ZS2, and ZS3 instruments to a final apical size of 25. Instrumentation was kept conservative because the primary objective was to disinfect the canal and preserve the thin root structure. Mechanical preparation was combined with chemical debridement, recognizing that shaping alone cannot contact all surfaces of the root canal system (Schilder, 1974; Peters, 2004).

The canal was irrigated throughout preparation with 2.5% sodium hypochlorite and 40% citric acid in a sequential protocol, with renewal of irrigant after each instrument. Final activation was performed with the EDDY sonic system (VDW GmbH, Munich, Germany) to improve irrigant exchange and promote removal of debris and smear layer from areas not directly contacted by instruments (Zehnder, 2006; Plotino et al., 2019; Violich & Chandler, 2010; Urban et al., 2017).

After chemomechanical preparation, the canal was dried with sterile paper points and obturated by cold lateral condensation of gutta-percha with Edge Bioceramic Sealer (EdgeEndo, Albuquerque, NM, USA), a premixed hydraulic calcium-silicate sealer. Hydraulic calcium-silicate sealers have favorable handling, biocompatibility, alkaline pH, and bioactive potential, although the clinical outcome depends on the entire treatment protocol instead of the sealer alone (Aminoshariae et al., 2022; Raman & Camilleri, 2024; Kapralos & Zehnder, 2026).



Fig. 6. Intraoperative periapical radiograph confirming the position of the guided drill along the planned canal trajectory.



Fig. 7. Master cone radiograph showing the gutta-percha cone positioned at the established working length before obturation.

The access cavity was restored at the same appointment with an adhesive nanohybrid composite resin (G-ænial Posterior, shade A3; GC Corporation, Tokyo, Japan). As shown in Figure 8, immediate postoperative radiographic and CBCT assessment confirmed obturation to the established working length, preservation of root integrity, and absence of perforation or canal deviation. A definitive coronal seal was placed promptly because both the quality of the root filling and the integrity of the coronal restoration influence endodontic outcome (Ray & Trope, 1995; Gillen et al., 2011). The procedure was completed without instrument separation or other intraoperative complications. The patient was referred to her general dentist for fabrication of a custom occlusal night guard to reduce parafunctional loading.

Outcome and follow-up

At the 1-week review, the patient reported complete resolution of symptoms. Tooth 28 was no longer tender to percussion, and mastication was comfortable. At 6 months, the tooth remained asymptomatic and functional. Follow-up imaging showed a reduction in the dimensions of the periapical radiolucency and early trabecular bone regeneration (Figure 9).

No clinical signs or symptoms were present at the 12-month recall. Cone beam computed tomography images demonstrated substantial additional bone regeneration and near-complete resolution of the original radiolucency (Figure 10). Progressive reduction of the periapical radiolucency together with the absence of symptoms is consistent with favorable healing after primary root canal treatment (Ng et al., 2008). Cone beam computed tomography can depict changes in periapical bone more sensitively than periapical radiography. Nevertheless, this advantage must be balanced against the additional radiation exposure (Patel et al., 2012).

Discussion

This case combines two diagnostic and technical problems: pulpal necrosis in a tooth without an obvious route of infection and extensive pulp canal obliteration that made conventional canal localization hazardous. Although the favorable outcome is clinically encouraging, the interpretation should distinguish direct observations from etiologic inference. Pulp necrosis, tenderness to percussion, and apical radiolucency were supported by clinical and imaging findings. In contrast, the proposed role of an occult crack was not directly demonstrated.

A necrotic pulp in a tooth without caries, a restoration, or a history of luxation injury should prompt a systematic search for less obvious pathways of infection. Longitudinal cracks may be difficult to identify because their dimensions are usually below the resolution of routine radiography and CBCT.



Fig. 8. Immediate postoperative outcome. (A) Periapical radiograph showing root canal obturation to the established working length. (B) Clinical view of the obturated canal before definitive restoration. (C) Postoperative CBCT views demonstrating conservative canal localization, preservation of root integrity, and three-dimensional obturation of the previously calcified canal.

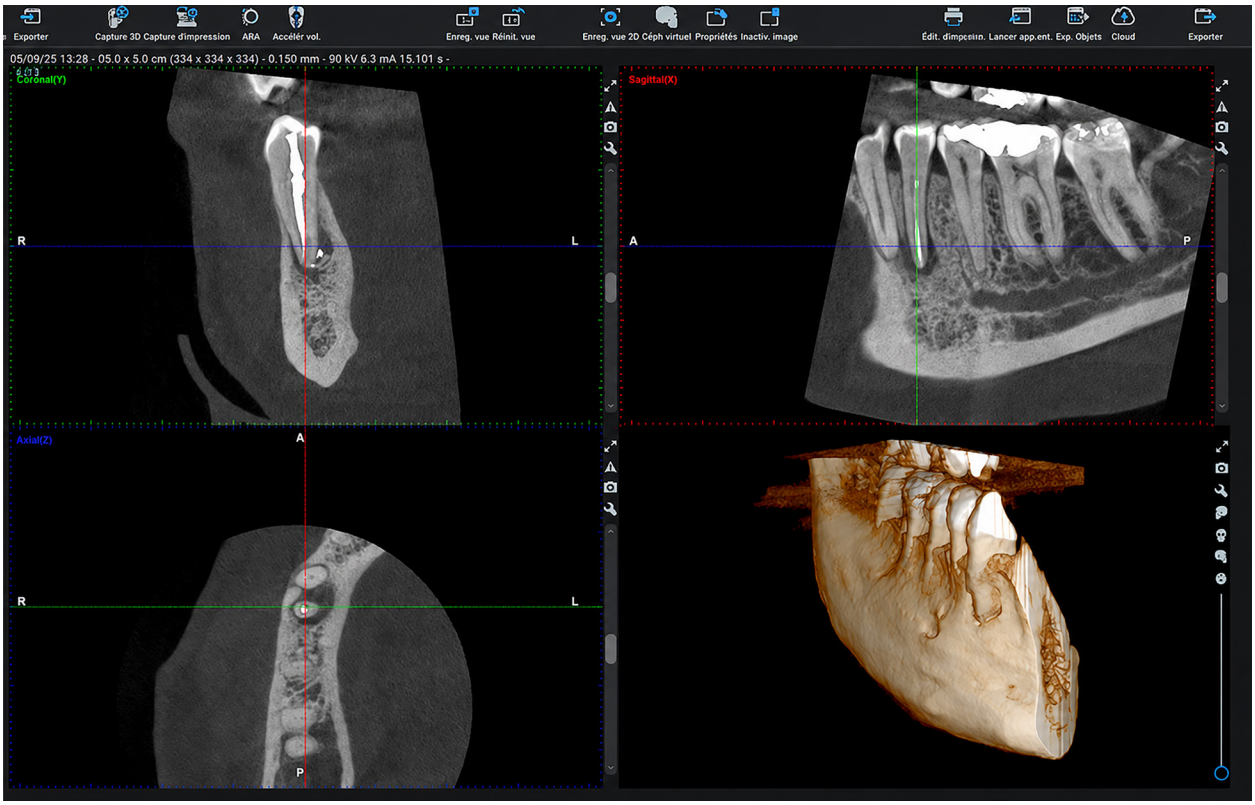

Fig. 9. Six-month follow-up CBCT examination showing reduction of the periapical radiolucency and early re-establishment of trabecular bone architecture.

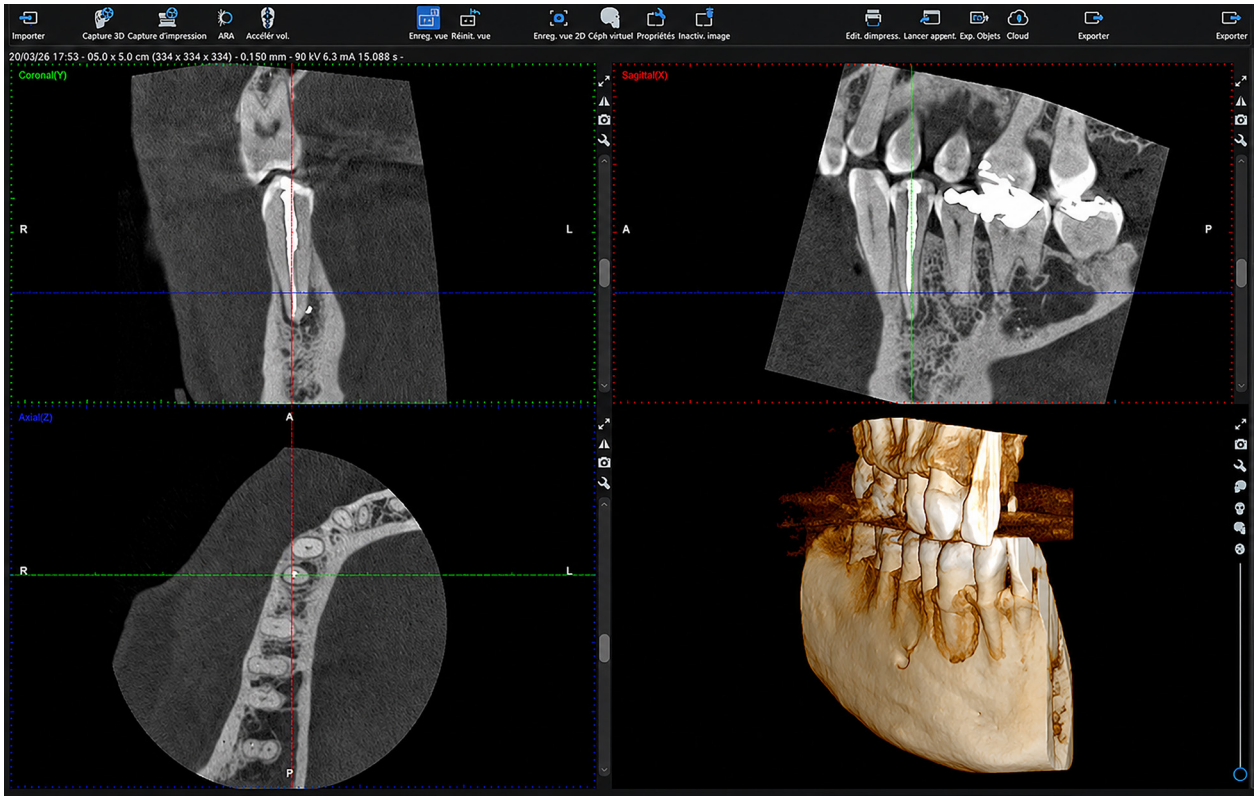

Fig. 10. Twelve-month CBCT assessment. Sagittal, coronal, axial, and three-dimensional reconstructions demonstrate advanced periapical healing, restoration of trabecular bone architecture, and marked reduction of the preoperative radiolucency.

The crack may also be concealed beneath intact enamel or extend in a plane that is not accessible to direct inspection. The absence of an isolated deep periodontal probing defect reduces concern for a full-thickness fracture communicating with the periodontium but does not exclude a more limited dentinal crack. Fracture-related pulp necrosis has therefore been proposed when a nonvital tooth lacks the usual etiologic factors (Berman & Kuttler, 2010). In the present case, nocturnal clenching increased the plausibility of repetitive fatigue loading; however, clenching is common, and no causal link can be established from history alone (Lynch & McConnell, 2002; Banerji et al., 2010a). Other unrecognized causes, including remote minor trauma or a developmental defect, cannot be excluded.

Pulp canal obliteration by itself is not an indication for root canal treatment. Many calcified teeth remain asymptomatic and do not develop apical disease. Intervention was indicated here because the tooth had a necrotic pulp, percussion tenderness, and apical pathosis. Once treatment was required, the degree and location of calcification shifted the risk-benefit balance away from exploratory freehand access. Continued drilling through an apparently solid dentin mass can rapidly produce an eccentric preparation, particularly in a narrow mandibular premolar root. Preservation of pericervical dentin is desirable. However, the principal objective is not simply to create the smallest possible cavity; it is to establish reproducible access that permits disinfection without weakening or perforating the root (Clark & Khademi, 2010).

The digital workflow was appropriate because CBCT revealed a targetable canal lumen apical to the calcified segment. Static guided endodontics transforms that lumen into a virtual endpoint and constrains the drill to a planned path. In vitro studies have reported higher canal location rates and substantially less substance loss with guided access than with conventional preparation under certain experimental conditions (Connert et al., 2019). Miniaturized systems have also improved the feasibility of guided treatment in teeth with narrow roots (Connert et al., 2025). These findings are consistent with the conservative access achieved in this case. However, the findings should not be interpreted as proof that guided access is universally superior. Experienced operators using magnification and careful freehand techniques may achieve excellent results. The comparative evidence are also heavily weighted toward laboratory studies, technical reports, and case series (Moreno-Rabié et al., 2020).

Both static and dynamic navigation employ CBCT-based virtual planning but differ in how the planned trajectory is transferred to the tooth. Static navigation uses a prefabricated template and sleeve to constrain the drill mechanically and to provide a reproducible pathway with comparatively modest intraoperative visuomotor demand. Its disadvantages include the need for a surface scan, digital registration, guide design and fabrication, sufficient interocclusal space for the guide-sleeve-drill assembly, and accurate guide seating throughout drilling. Once the guide has been fabricated, the trajectory cannot be modified without redesigning it. Dynamic navigation tracks a calibrated handpiece and a jaw-mounted reference marker and displays the bur position, angulation, and depth in real time. The absence of a physical template preserves visibility and access for cooling and irrigation, permits same-appointment treatment, and allows intraoperative modification of the entry point or trajectory. These advantages are balanced by equipment cost, calibration sensitivity, possible obstruction of optical tracking, and the need to coordinate drilling in the operative field with continuous observation of a navigation display (Connert et al., 2022; Ribeiro et al., 2022).

Direct comparative evidence has not established universal superiority of either navigation method. In an in vitro study using anatomically challenging three-dimensional printed teeth, static navigation

produced the smallest angular, entry-point, and drill-tip deviations and required less time than dynamic navigation. Dynamic navigation removed the least tooth structure, and canal-location success was high with both methods (Huth et al., 2024). The real-time flexibility of dynamic navigation is accompanied by a meaningful learning curve. A simulation study found similar geometric precision for experienced and less experienced operators, but the less experienced operator required longer drilling and visuomotor coordination times and experienced more procedural mishaps (Restrepo-Restrepo et al., 2025). Clinical failures related to handpiece adaptation, calibration, and loss of trajectory have also been reported. These failures include canal deviation or failure to locate the canal in 2 of 7 dynamically navigated teeth (Yang et al., 2024). For the present single-rooted premolar, the straight root, clearly identifiable apical target, stable tooth-supported guide, and adequate access space favored static navigation. Dynamic navigation may be preferable when guide fabrication is impractical, multiple trajectories are required, access space prevents guide placement, or intraoperative alteration of the planned path is anticipated, provided that calibration and operator training are adequate.

Accuracy is cumulative rather than determined by a single component. Potential error may arise during CBCT acquisition, surface scanning, DICOM-STL registration, virtual trajectory selection, guide fabrication, sleeve placement, guide seating, and drilling. Even small angular or linear deviations may become clinically important as drilling depth increases. For this reason, the planned path should be centered within the root in multiple planes, guide seating should be confirmed before and after isolation, and progression should be checked periodically. The single, relatively straight canal and stable tooth-supported guide were favorable features in this patient. More complex anatomy, limited interocclusal space, restricted mouth opening, posterior location, metallic image artifacts, root curvature, or an extremely thin root may reduce feasibility or require a different approach (Krastl et al., 2016; Zehnder et al., 2016; Moreno-Rabié et al., 2020).

Guided access solves canal localization, not the entire endodontic procedure. After the calcified segment was traversed, small stainless steel files were required to negotiate the residual lumen and establish a reproducible glide path. Conservative rotary preparation then created sufficient space for irrigant exchange without unnecessary enlargement of the narrow root. This distinction is important because successful treatment of a necrotic canal depends on microbial reduction throughout the root canal system, including surfaces and irregularities that instruments cannot contact (Schilder, 1974; Peters, 2004; Ricucci & Siqueira, 2010).

The obturation and restorative phases were also relevant to the observed healing. A calcium-silicate sealer was used with gutta-percha, but the favorable result cannot be attributed to a single material. Clinical success reflects the combined effects of access accuracy, canal negotiation, chemomechanical debridement, obturation, and prevention of coronal reinfection. The immediate bonded resin composite restoration limited the interval during which the treated canal could be exposed to oral fluids (Chen et al., 2023). The occlusal guard was prescribed as a protective measure in view of the clenching history, although its ability to prevent progression of an unconfirmed microcrack in this individual cannot be determined.

Clinical resolution within 1 week and progressive radiographic bone repair at 6 and 12 months are consistent with a favorable short-term outcome. Nevertheless, follow-up imaging requires careful justification. Cone beam computed tomography is more sensitive than periapical radiography for detecting and monitoring periapical changes. However, routine serial CBCT is not indicated solely to document healing. In most cases, clinical

examination and standardized periapical radiographs should be the primary follow-up methods, with limited-field CBCT reserved for situations in which the anticipated information may alter management (Patel et al., 2012, 2019). The availability of CBCT follow-up in this report provided three-dimensional visualization of healing. However, it should not be viewed as a mandatory surveillance protocol.

Several limitations should be acknowledged. This is a single case with a 12-month observation period. The suspected crack was not visualized, stained, transilluminated, or histologically confirmed, and the causal relationship between clenching and pulp necrosis therefore remains speculative. Dentin preservation was judged from the planned and postoperative images but was not quantified volumetrically. No freehand comparison was possible, and the contribution of individual treatment components cannot be separated. Longer clinical and radiographic follow-up is needed to determine whether healing is sustained and whether an occult structural defect affects long-term tooth survival.

Conclusion

Static guided endodontic access enabled conservative and accurate localization of a severely calcified canal in a clinically intact mandibular right first premolar with pulp necrosis and symptomatic apical periodontitis. The treatment was followed by resolution of symptoms and progressive periapical healing through 12 months. An occult crack associated with nocturnal clenching was a plausible route of bacterial ingress but could not be confirmed. Careful case selection, precise digital registration, stable guide seating, controlled drilling, and complete chemomechanical treatment remain essential. The outcome of this single case supports guided access as a useful adjunct for selected calcified canals but does not establish superiority over well-executed conventional treatment.

Ethical considerations

Written informed consent was obtained from the patient for treatment and for publication of the clinical information and radiographic images included in this report.

Acknowledgments

This work received no external funding.

References

Aminoshariae, A., Primus, C., & Kulild, J. C. (2022). Tricalcium silicate cement sealers: Do the potential benefits of bioactivity justify the drawbacks? Journal of the American Dental Association 153(8), 750–760. https://doi.org/10.1016/j.adaj.2022.01.004

Banerji, S., Mehta, S. B., & Millar, B. J. (2010a). Cracked tooth syndrome. Part 1: Aetiology and diagnosis. British Dental Journal, 208(10), 459-463. https://doi.org/10.1038/sj.bdj.2010.449

Banerji, S., Mehta, S. B., & Millar, B. J. (2010b). Cracked tooth syndrome. Part 2: Restorative options for the management of cracked tooth syndrome. British Dental Journal, 208(11), 503-514. https://doi.org/10.1038/sj.bdj.2010.496

Berman, L. H., & Kuttler, S. (2010). Fracture necrosis: Diagnosis, prognosis assessment, and treatment recommendations. Journal of Endodontics, 36(3), 442-446. https://doi.org/10.1016/j.joen.2009.12.018

Chen, P., Chen, Z., Teoh, Y. Y., Peters, O. A., & Peters, C. I. (2023). Orifice barriers to prevent coronal microleakage after root canal treatment: systematic review and meta-analysis. Australian Dental Journal, 68(2), 78–91. https://doi.org/10.1111/adj.12951

Clark, D., & Khademi, J. (2010). Modern molar endodontic access and directed dentin conservation. Dental Clinics of North America, 54(2), 249-273. https://doi.org/10.1016/j.cden.2010.01.001

Connert, T., Krug, R., Eggmann, F., Emsermann, I., ElAyouti, A., Weiger, R., Kühl, S., & Krastl, G. (2019). Guided endodontics versus conventional access cavity preparation: A comparative study on substance loss using three-dimensional-printed teeth. Journal of Endodontics, 45(3), 327-331. https://doi.org/10.1016/j.joen.2018.11.006

Connert, T., Walter, E., Benz, L., Schwendicke, F., & Leontiev, W. (2025). Guided endodontics-potential and limitations. Australian Dental Journal, 70 Suppl 1, S118–S128. https://doi.org/10.1111/adj.70012

Connert, T., Weiger, R., & Krastl, G. (2022). Present status and future directions - Guided endodontics. International Endodontic Journal, 55 Suppl 4, 995–1002. https://doi.org/10.1111/iej.13687

Connert, T., Zehnder, M. S., Weiger, R., Kühl, S., & Krastl, G. (2017). Microguided endodontics: Accuracy of a miniaturized technique for apically extended access cavity preparation in anterior teeth. Journal of Endodontics, 43(5), 787-790. https://doi.org/10.1016/j.joen.2016.12.016

Gillen, B. M., Looney, S. W., Gu, L. S., Loushine, B. A., Weller, R. N., Loushine, R. J., Pashley, D. H., & Tay, F. R. (2011). Impact of the quality of coronal restoration versus

the quality of root canal fillings on success of root canal treatment: A systematic review and meta-analysis. Journal of Endodontics, 37(7), 895-902. https://doi.org/10.1016/j.joen.2011.04.002

Huth, K. C., Borkowski, L., Liebermann, A., Berlinghoff, F., Hickel, R., Schwendicke, F., & Reymus, M. (2024). Comparing accuracy in guided endodontics: dynamic real-time navigation, static guides, and manual approaches for access cavity preparation - an in vitro study using 3D printed teeth. Clinical Oral Investigations, 28(4), 212. https://doi.org/10.1007/s00784-024-05603-8

Kapralos, V., & Zehnder, M. (2026). Physico-chemical analysis of eight pre-mixed hydraulic silicate sealers. Frontiers in Dental Medicine, 7, 1851537. https://doi.org/10.3389/fdmed.2026.1851537

Krastl, G., Zehnder, M. S., Connert, T., Weiger, R., & Kühl, S. (2016). Guided endodontics: A novel treatment approach for teeth with pulp canal calcification and apical pathology. Dental Traumatology, 32(3), 240-246. https://doi.org/10.1111/edt.12235

Lynch, C. D., & McConnell, R. J. (2002). The cracked tooth syndrome. Journal of the Canadian Dental Association, 68(8), 470-475.

Moreno-Rabié, C., Torres, A., Lambrechts, P., & Jacobs, R. (2020). Clinical applications, accuracy and limitations of guided endodontics: A systematic review. International Endodontic Journal, 53(2), 214-231. https://doi.org/10.1111/iej.13216

Ng, Y.-L., Mann, V., Rahbaran, S., Lewsey, J., & Gulabivala, K. (2008). Outcome of primary root canal treatment: Systematic review of the literature-Part 2. Influence of clinical factors. International Endodontic Journal, 41(1), 6-31. https://doi.org/10.1111/j.1365-2591.2007.01323.x

Patel, S., Brown, J., Semper, M., Abella, F., & Mannocci, F. (2019). European Society of Endodontology position statement: Use of cone beam computed tomography in Endodontics: European Society of Endodontology (ESE) developed by. International Endodontic Journal, 52(12), 1675–1678. https://doi.org/10.1111/iej.13187

Patel, S., Wilson, R., Dawood, A., Foschi, F., & Mannocci, F. (2012). The detection of periapical pathosis using digital periapical radiography and cone beam computed tomography-Part 2: A 1-year post-treatment follow-up. International Endodontic Journal, 45(8), 711-723. https://doi.org/10.1111/j.1365-2591.2012.02076.x

Peters, O. A. (2004). Current challenges and concepts in the preparation of root canal systems: A review. Journal of Endodontics, 30(8), 559-567. https://doi.org/10.1097/01.don.0000129039.59003.9d

Plotino, G., Grande, N. M., Mercadé, M., Cortese, T., Staffoli, S., Gambarini, G., & Testarelli, L. (2019). Efficacy of sonic and ultrasonic irrigation devices in the removal of debris from canal irregularities in artificial root canals. Journal of Applied Oral Science, 27, e20180045. https://doi.org/10.1590/1678-7757-2018-0045

Raman, V., & Camilleri, J. (2024). Characterization and assessment of physical properties of 3 single syringe hydraulic cement-based sealers. Journal of Endodontics, 50(3), 381–388. https://doi.org/10.1016/j.joen.2024.01.001

Ray, H. A., & Trope, M. (1995). Periapical status of endodontically treated teeth in relation to the technical quality of the root filling and the coronal restoration. International Endodontic Journal, 28(1), 12-18. https://doi.org/10.1111/j.1365-2591.1995.tb00150.x

Restrepo-Restrepo, F. A., Cardona-Alzate, D. P., Muriel-Urrego, B. J., Villa-Machado, P. A., & Tobón-Arroyave, S. I. (2025). Computer-assisted Dynamic Navigation for Localizing Severely Calcified Root Canals: An Analysis of Deviations, Task-focused Performance, and Operator Perception. Journal of Endodontics, 51(9), 1265–1277. https://doi.org/10.1016/j.joen.2025.06.008

Ribeiro, D., Reis, E., Marques, J. A., Falacho, R. I., & Palma, P. J. (2022). Guided endodontics: static vs. dynamic computer-aided techniques - A literature review. Journal of Personalized Medicine, 12(9), 1516. https://doi.org/10.3390/jpm12091516

Ricucci, D., & Siqueira, J. F., Jr. (2010). Biofilms and apical periodontitis: Study of prevalence and association with clinical and histopathologic findings. Journal of Endodontics, 36(8), 1277-1288. https://doi.org/10.1016/j.joen.2010.04.007

Schilder, H. (1974). Cleaning and shaping the root canal. Dental Clinics of North America, 18(2), 269-296.

Urban, K., Donnermeyer, D., Schäfer, E., & Bürklein, S. (2017). Canal cleanliness using different irrigation activation systems: A scanning electron microscopic evaluation. Clinical Oral Investigations, 21(9), 2681-2687. https://doi.org/10.1007/s00784-017-2070-x

Violich, D. R., & Chandler, N. P. (2010). The smear layer in endodontics-A review. International Endodontic Journal, 43(1), 2-15. https://doi.org/10.1111/j.1365-2591.2009.01627.x

Yang, X., Zhang, Y., Chen, X., Huang, L., & Qiu, X. (2024). Limitations and management of dynamic navigation system for locating calcified canals failure. Journal of Endodontics, 50(1), 96–105. https://doi.org/10.1016/j.joen.2023.10.010

Zehnder, M. (2006). Root canal irrigants. Journal of Endodontics, 32(5), 389-398. https://doi.org/10.1016/j.joen.2005.09.014

Zehnder, M. S., Connert, T., Weiger, R., Krastl, G., & Kühl, S. (2016). Guided endodontics: Accuracy of a novel method for guided access cavity preparation and root canal location. International Endodontic Journal, 49(10), 966-972. https://doi.org/10.1111/iej.12544